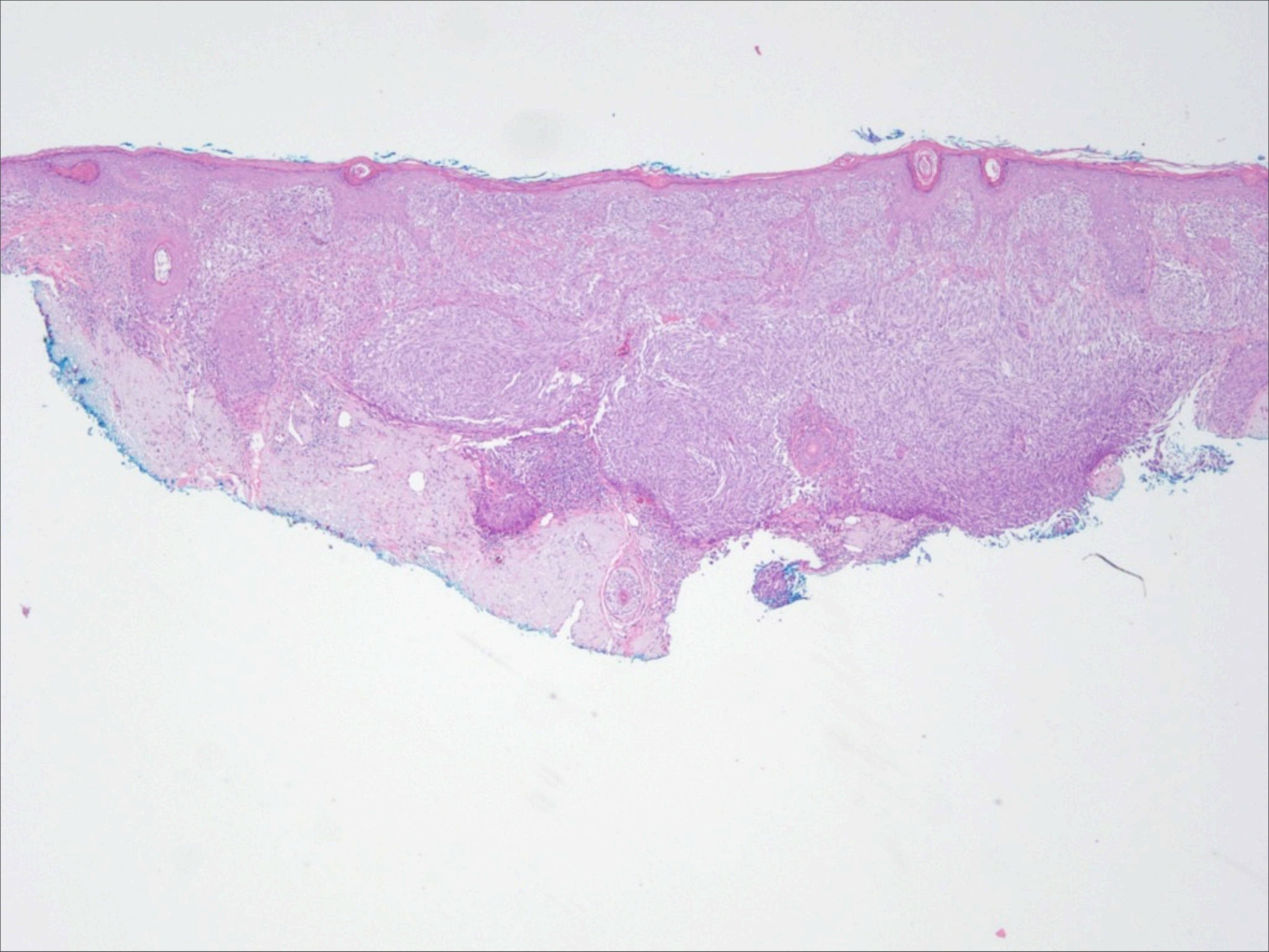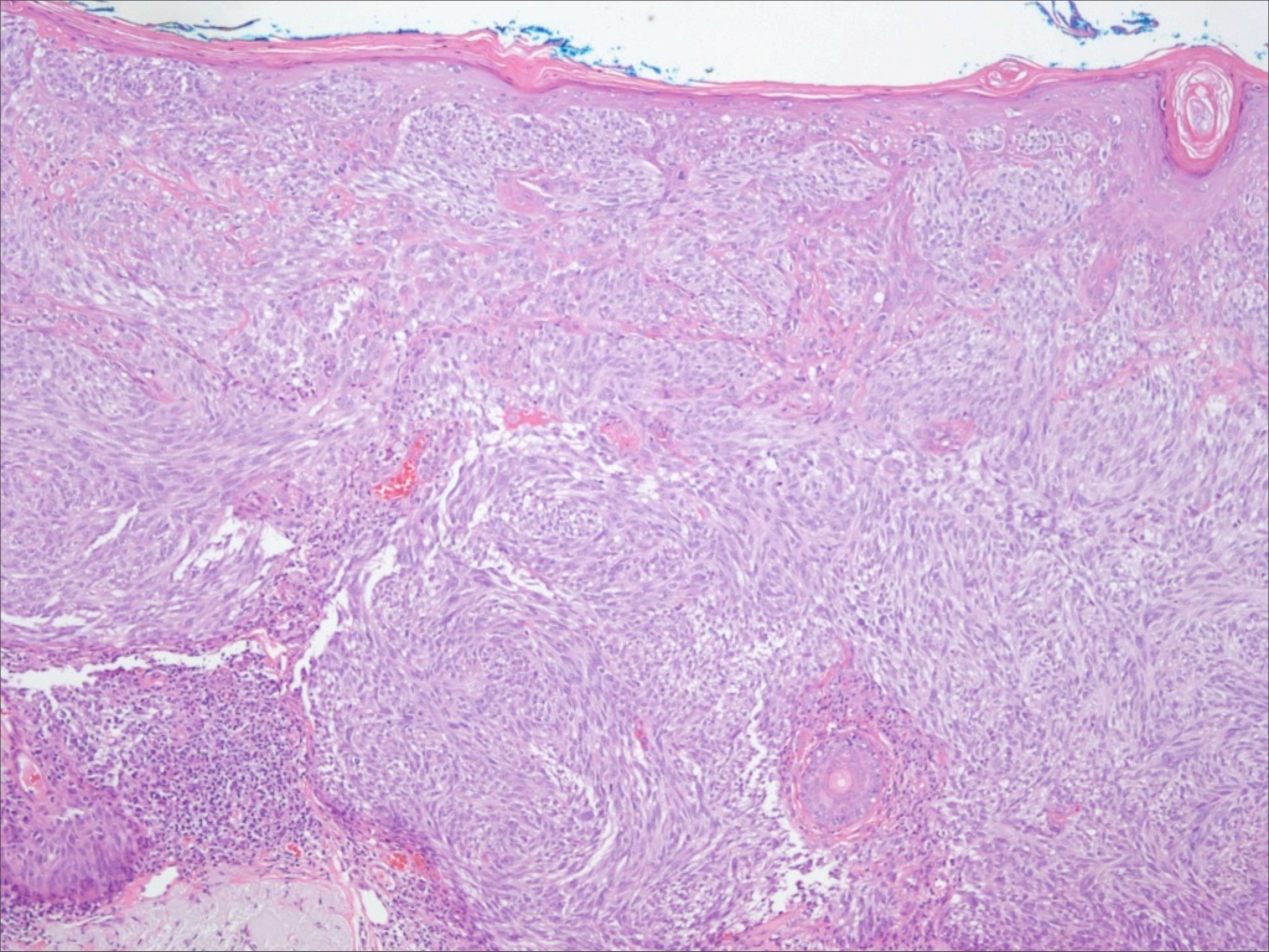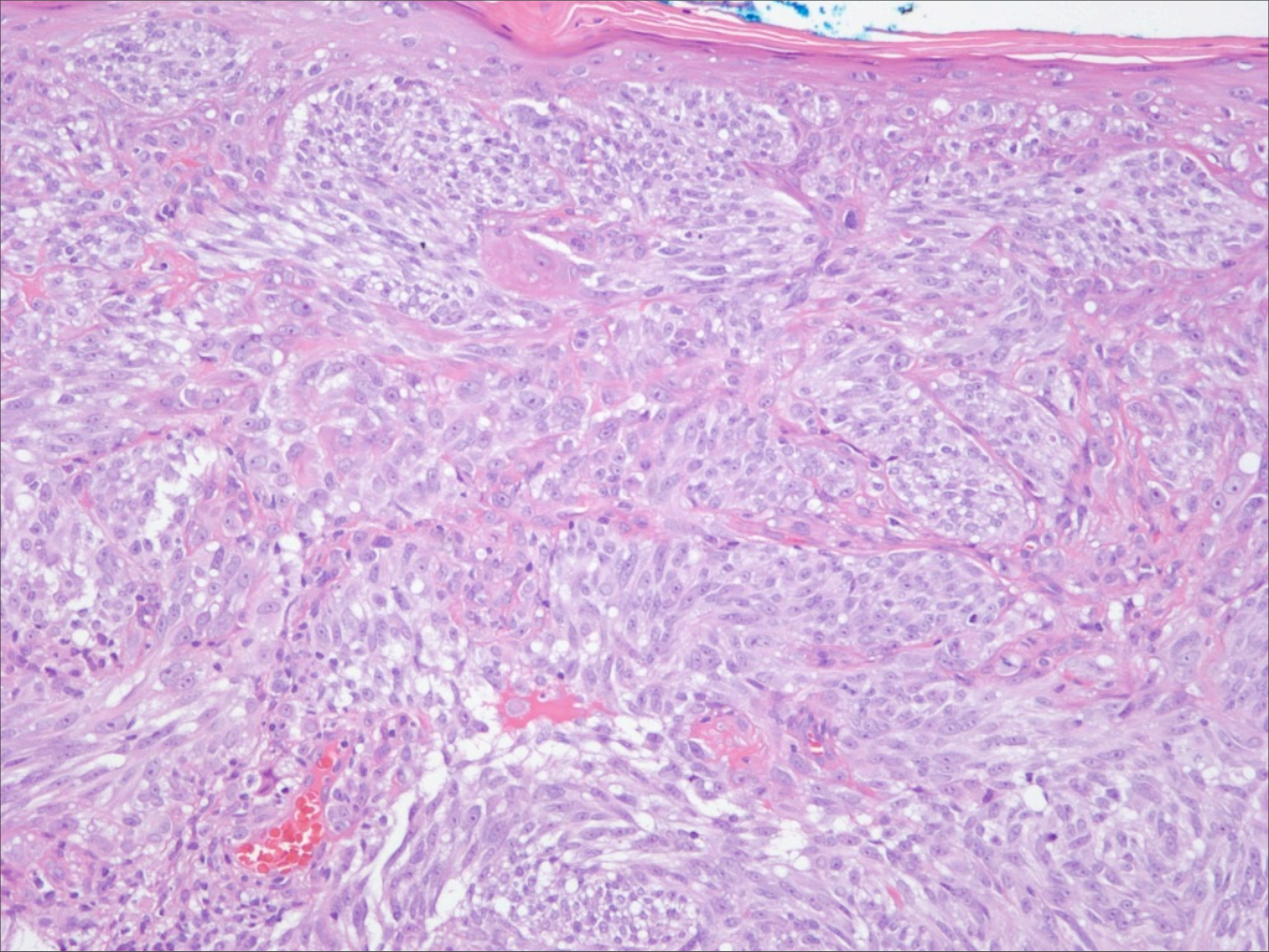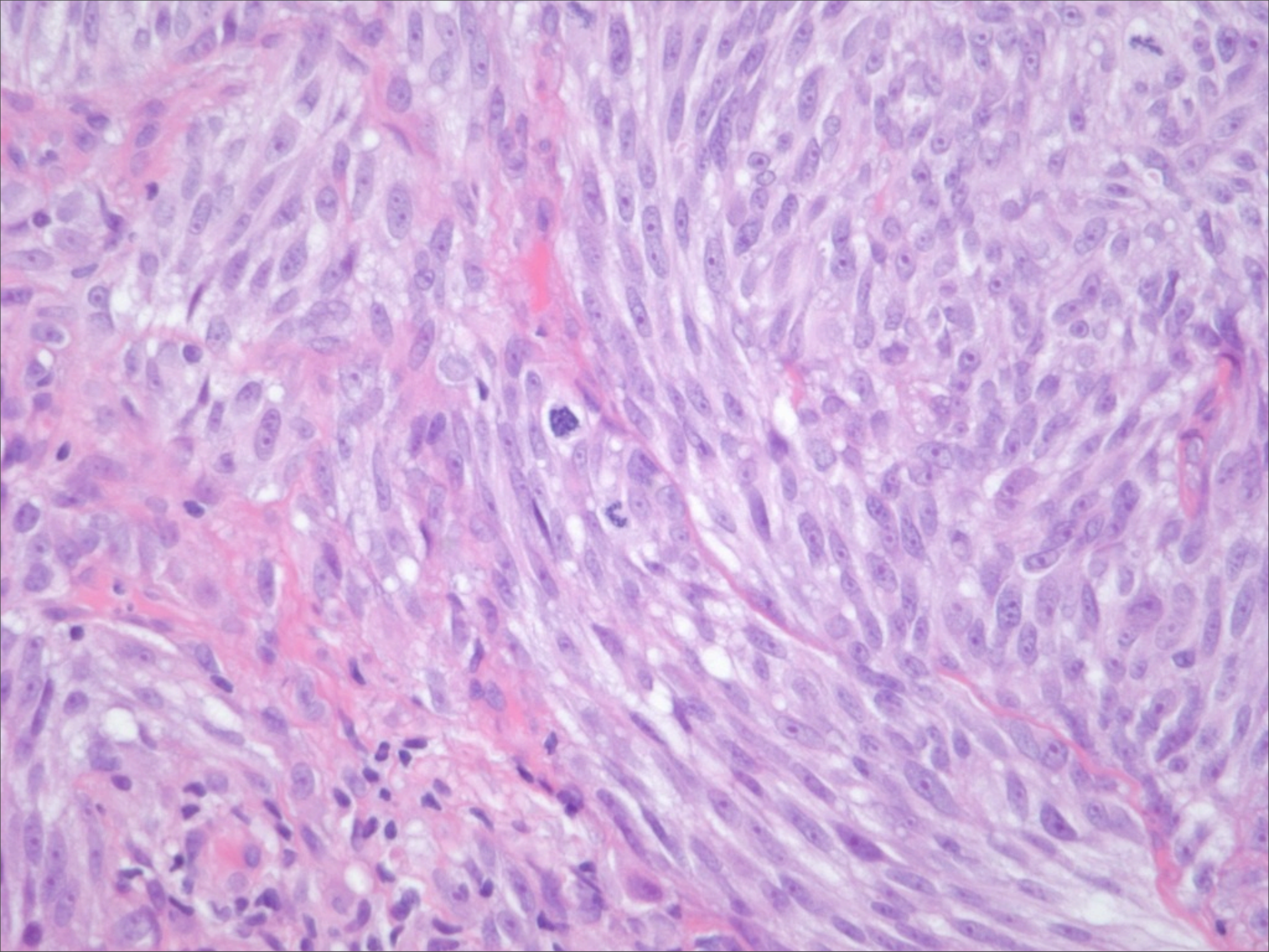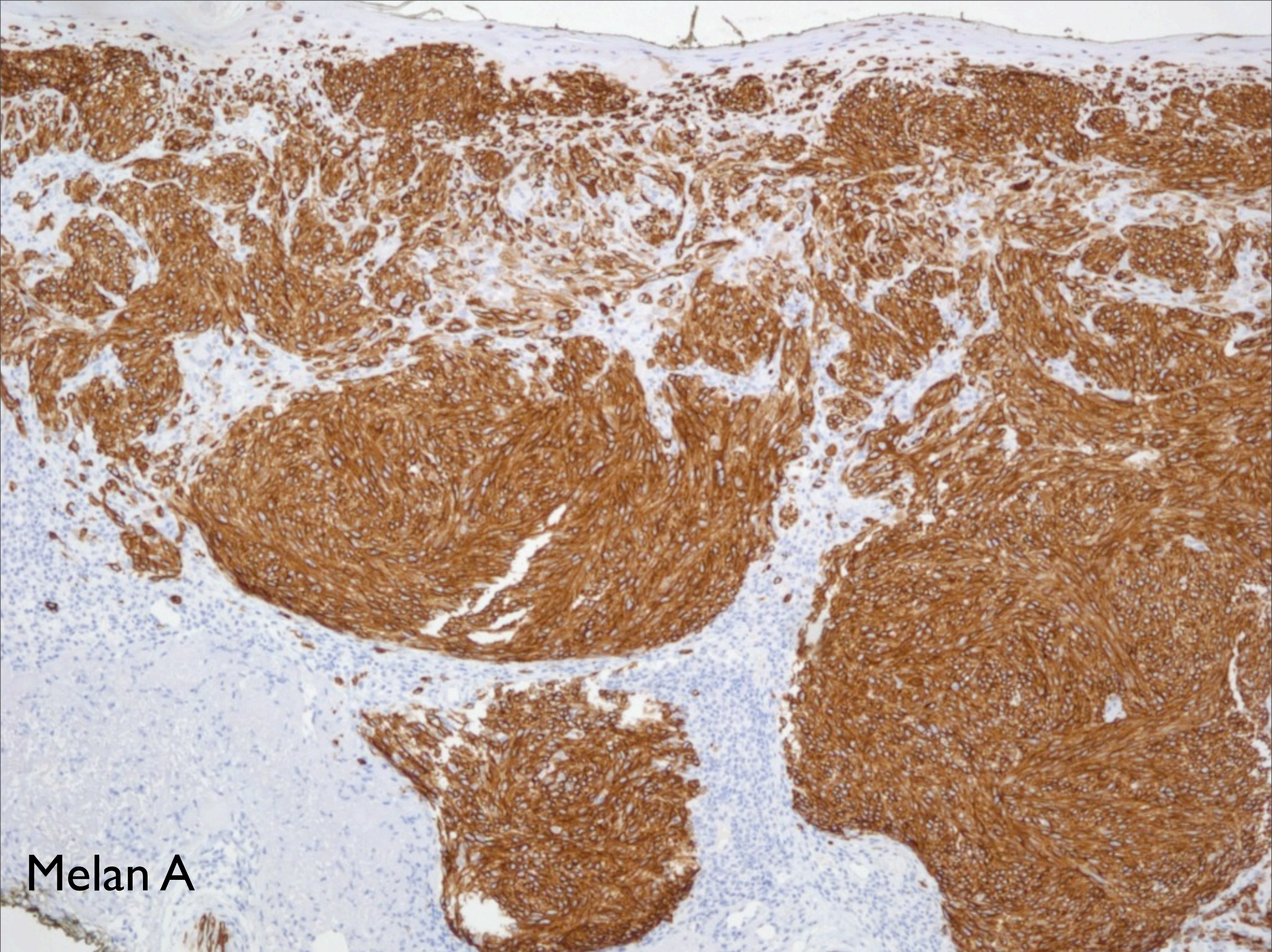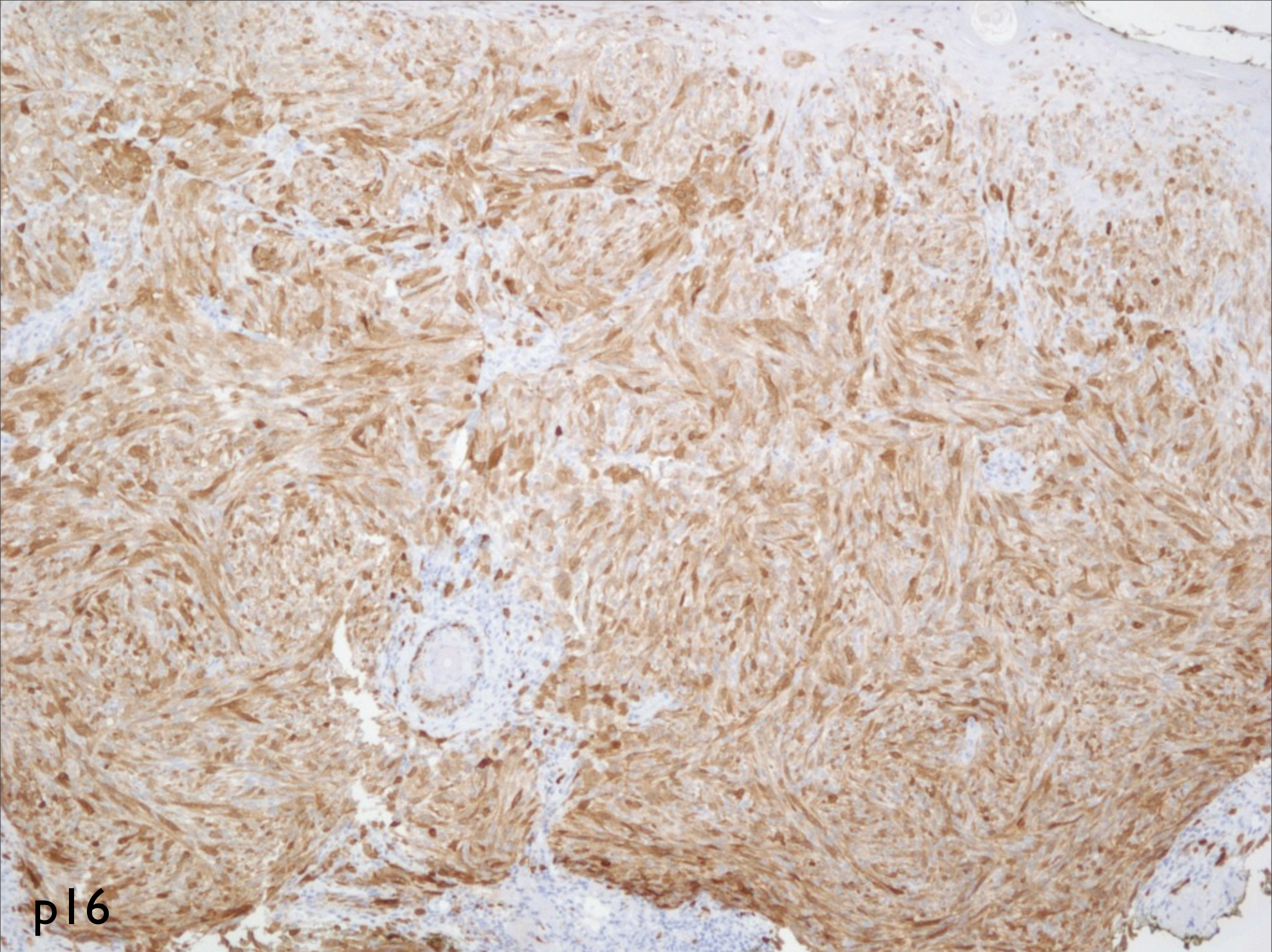
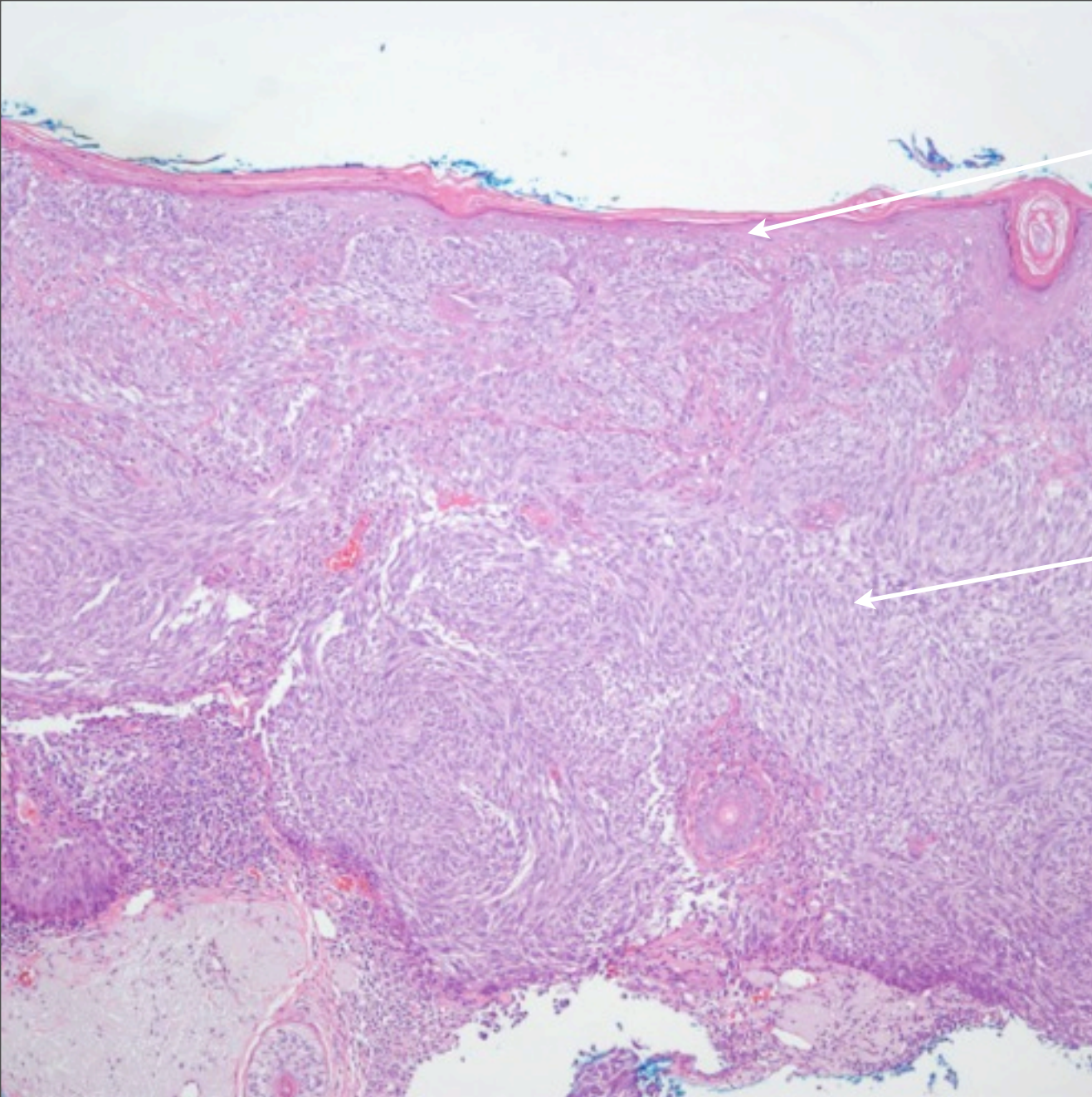


Melan A



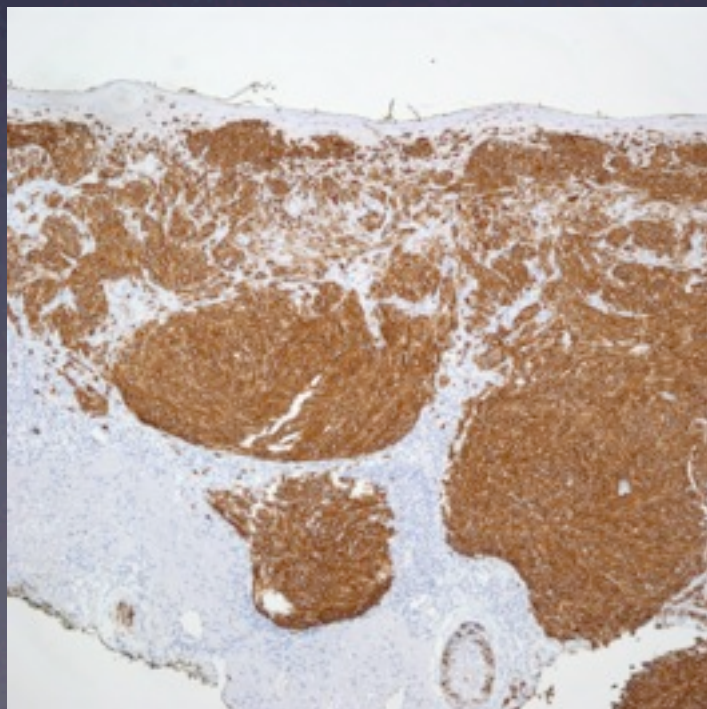
p16

Malignant Melanoma, Amelanotic Type



Junctional Nests

Pleomorphic Spindle Cells



Confirm with
Immunohistochemistry